

Therapeutic options for cervicogenic headache

Expert Rev. Neurother. 14(1), 39–49 (2014)

César Fernández-de-
las-Peñas*^{1–3} and
María L Cuadrado^{4,5}

¹Department of Physical Therapy, Occupational Therapy, Physical Medicine and Rehabilitation, Universidad Rey Juan Carlos, Alcorcón, Madrid, Spain

²Laboratory of Esthesiology, Universidad Rey Juan Carlos, Alcorcón, Madrid, Spain

³Cátedra de Investigación y Docencia en Fisioterapia: Terapia Manual y Punción Seca, Universidad Rey Juan Carlos, Alcorcón, Madrid, Spain

⁴Headache Unit, Department of Neurology, Hospital Clínico San Carlos, Madrid, Spain

⁵Department of Medicine, Universidad Complutense, Madrid, Spain

*Author for correspondence:

Tel.: +34 914 888 884

Fax: +34 914 888 957

cesar.fernandez@urjc.es

The term cervicogenic headache (CeH) describes a syndrome originating from the cervical spine. There are a variety of therapeutic approaches used for the management of CeH, but scientific evidence of their effectiveness is scarce. No medication drug has proven to be effective. The evidence for greater occipital nerve blocks, cervical nerve blockades, facet joint injections and surgical procedures is limited. Several physical therapy interventions are proposed for CeH, with spinal manipulation and soft tissue interventions being the most commonly used. However, the lack of solid evidence of positive effects and risks of serious complications for spinal manipulation should be considered in favor of other physical therapy interventions associated with less risk. The inconsistent results in the literature can be related to the fact that maybe not all therapeutic interventions are appropriate for all patients with CeH or maybe not all patients with CeH will benefit from particular interventions.

KEYWORDS: cervicogenic headache • headache • manual therapy • neck • nerve blocks • physical therapy

The idea that headaches may originate in the cervical spine or the adjacent soft tissues has been discussed over decades, and still is a matter of debate. The term cervicogenic headache (CeH) was first introduced in 1983 by Sjaastad *et al.* to describe a headache syndrome that was believed to originate from the cervical spine [1]. Early descriptions characterized CeH as a unilateral or mainly unilateral headache, starting posteriorly but advancing to the frontal area, usually accompanied by ipsilateral arm discomfort, reduced cervical range of motion and mechanical precipitation of attacks. A positive effect of anesthetic blockades on the symptomatic side was said to be confirmatory. Nevertheless, there has been some controversy regarding whether the signs and symptoms of neck involvement represent a true cervical source for head pain. CeH has to be differentiated from other headaches, particularly migraine, tension-type headache or hemicrania continua. In the clinical setting, there is considerable overlap among these headaches, and no consensus exists on a definite diagnosis of CeH. This situation can be related to the fact that different diagnostic criteria have emerged over time [2–4]. Diagnostic criteria of CeH have been recently revised and modified in the third edition of the International Classification of the Headache

Disorders (11.2. Headache attributed to disorders of the neck – 11.2.1 CeH; Box 1) [5].

Precise estimates of incidence and prevalence of CeH differ according to the populations included and the diagnostic criteria used in epidemiological studies. The most accepted prevalence for CeH, using clinical criteria for diagnosis, ranges from 1 to 4.1% of the general population, without a clear predominance of males or females [6–8]. However, Knackstedt *et al.* observed that the prevalence of CeH was 0.17% in the general population with a female preponderance [9].

The neuroanatomical basis for CeH seems to be located in the trigeminocervical nucleus caudalis of the spinal gray matter at C1–C3 levels [10]. In this nucleus, nociceptive afferents from the upper cervical spinal nerves converge onto second-order neurons that also receive afferents from the first division of the trigeminal nerve, via the trigeminal nerve spinal tract [11]. The topographic arrangement of the trigeminocervical nucleus caudalis allows the interchange of nociceptive information of the upper cervical spinal nerves and the ophthalmic division of the trigeminal nerve, which explains that the pain from a cervical source may be referred to the forehead, temple or orbit. Therefore, every cervical structure innervated by the trigeminocervical nucleus caudalis (joints, muscles, nerves, ligaments, dura) can

Box 1. Diagnostic criteria for cervicogenic headache (according to the International Classification of Headache Disorders[†]).

Description

Headache caused by a disorder of the cervical spine and its component bony, disc and/or soft tissue elements, usually but not invariably accompanied by neck pain

Diagnostic criteria

- Any headache fulfilling criterion C
- Clinical, laboratory and/or imaging evidence of a disorder or lesion within the cervical spine or soft tissues of the neck, known to be able to cause headache
- Evidence of causation demonstrated by at least two of the following:
 - Headache has developed in temporal relation to the onset of the cervical disorder or appearance of the lesion
 - Headache has significantly improved or resolved in parallel with improvement in or resolution of the cervical disorder or lesion
 - Cervical range of motion is reduced and headache is made significantly worse by provocative maneuvers
 - Headache is abolished following diagnostic blockade of a cervical structure or its nerve supply
- Not better accounted for by another ICHD-3[†] diagnosis

[†]The International Classification of Headache Disorders, 3rd Edition (beta version) [5].

be implicated in the genesis of CeH [12]. However, Knackstedt did not find specific changes in MRI of craniovertebral structures in patients with CeH [13]. Some authors have also suggested that proinflammatory mediators, for example, cytokines, IL-1 β and TNF- α can be involved in the pathophysiology of CeH [14–16].

Many treatments have been proposed for CeH, but only few of them have been tested in randomized controlled trials, and even fewer have proven effective [17]. This is particularly important since it seems that CeH does not improve over time in contrast to other secondary headaches [18], so better therapeutic management of this headache would be clinically important. The current paper will discuss the medical and physical therapy options for the therapeutic management of patients with CeH.

Medical interventions for cervicogenic headache

Patients with CeH may be treated by different health care professionals (neurologists, rheumatologists, anesthesiologists, physical therapists, orthopedic surgeons and neurosurgeons). In each case, the recommended treatment seems more dependent on the particular specialty of the professional in-charge of the patient than the research supporting it [19].

The existence of a wide range of therapies without clear effectiveness can be, in part, a product of an inconclusive understanding of the underlying pathology of CeH. Moreover, diagnostic criteria have changed over time, so the selection of patients has shown marked variations between different studies. Commonly used treatment options include medications, nerve blocks or local injections of anesthetics, physical therapy and surgery [20].

Oral medications

Individuals with CeH normally take analgesics or anti-inflammatory drugs to mitigate the pain [21]. Some patients are also prescribed antidepressants, antiepileptics or muscle relaxants [10,21]. However, none of these drugs have been rigorously studied in controlled trials, so none of them has demonstrated

efficacy for CeH [10,22]. In fact, when used as the only mode of treatment, medications do not generally provide substantial pain relief.

Drug responses may help differentiate CeH from other similar headaches. Unlike hemicrania continua, CeH does not show an absolute response to indomethacin [23]; unlike migraine, CeH does not respond to ergots or triptans [24,25].

Botulinum toxin injections

Botulinum toxin type A injections in the cervical muscles have been apparently helpful in some patients [26]. However, a recent randomized controlled trial did not demonstrate a beneficial effect of onabotulinum toxin type A in CeH [27]. In fact, to date, there is no sufficient evidence supporting a clinically relevant or a statistically significant effect of botulinum toxin injections in patients with chronic neck pain associated with or without associated CeH [28].

Greater occipital nerve blocks

Anesthetic blockades of the greater occipital nerves (GONs) are commonly used in CeH, both for diagnosis and treatment. However, the scientific evidence for their efficacy is limited, since the majority of studies are small or noncontrolled [29]. Naja *et al.* [30] were able to demonstrate efficacy in a double-blind, controlled trial with follow-up of 2 weeks. Fifty patients diagnosed with CeH were randomly divided into two groups that received injections of either an anesthetic mixture or placebo over the greater and lesser occipital nerves. Anesthetic blocks were significantly effective in reducing pain parameters. Furthermore, in an open study, the same authors found that repeated injections with the active drug could get longer periods of remission [31]. In a series of 28 patients with CeH, Inan *et al.* [32] found that the therapeutic effect obtained with GON blockades was similar to that achieved by blocking the C2/C3 nerves. In addition, several noncontrolled observational studies have reported favorable responses in over 70% of

patients receiving occipital nerve blocks either with anesthetics alone or with anesthetics plus corticosteroids [33–36]. Headache relief is already apparent in the first few minutes, which can support the diagnosis of CeH [34,36]. However, occipital nerve blocks can also arrest other headaches different to CeH, such as occipital neuralgia, cluster headache or migraine [37,38]. Baron *et al.* found that a wide spectrum of cervically mediated symptoms including neck range of motion, headache, neck pain and dizziness could respond to this procedure, and that certain examination findings might help to predict benefit from GON blockades [39].

Cervical nerve blockades, facet joint injections & epidural steroid injections

CeH may also be treated with anesthetic blockades of the cervical nerves (C1–C3) and/or facet joint injections [40]. Indeed, in a retrospective study, Narouze *et al.* found that lateral atlantoaxial (C1/C2) intra-articular corticosteroid injections could provide short-term analgesia lasting up to a few months in patients with atlantoaxial joint pain [41]. A chart review by Zhou *et al.* also showed that fluoroscopically guided C1/C2 and C2/C3 facet joint injections and C2–C3 spinal rami blocks with anesthetics and corticosteroids were effective and well tolerated for the treatment of CeH [42]. Martelletti *et al.* found that epidural steroid injection into the epidural cervical space at C6–C7 or C7–T1 level [43] was effective at short (12 h) and medium (4 weeks) terms [44] but not at long term [45] for the relief of pain in patients with CeH.

Surgical procedures

The last therapeutic option for patients with CeH seems to be surgery. The most studied surgical intervention is percutaneous radiofrequency neurotomy [10]. The major problem in evaluating this technique is the existence of several different approaches: radiofrequency neurotomy of C2 medial rami [46], radiofrequency neurotomy of C3–C6 medial rami [47] and radiofrequency neurotomy of sinuvertebral nerves of C3/C4 [48]. The results are conflicting since some studies have reported positive outcomes [49,50], whereas others have not [51]. In fact, Haspelslagh *et al.* did not find evidence that radiofrequency treatment of cervical facet joints and upper dorsal root ganglions was more effective than GON blockade in patients with CeH [52].

Some authors propose the use of pulsed radiofrequency as a potential treatment for patients with CeH related to the C2 nerve [53–56]. The main difference with continuous radiofrequency is that pulsed radiofrequency delivers high-intensity currents in pulses, making heat dissipate so that temperatures are not as neurodestructive. It seems that radiofrequency should be particularly applicable for the treatment of headache stemming from the C2–C3 zygapophyseal joints, in which case the target nerve is the third occipital nerve.

Other surgical option is decompression and microsurgical neurolysis of the C2 spinal nerve, with excision of scars as well as ligamentous and vascular elements that produce nerve compression [57]. Again, evidence of its effectiveness is scarce.

Occipital nerve stimulation is emerging as a promising therapy for some patients with refractory and intractable headaches. This form of neuromodulation involves surgical positioning of leads containing electrodes under the skin of the occipital region. The leads are energized with electrical signals coming from an internal pulse generator. Rodrigo-Royo *et al.* reported that occipital nerve stimulation was effective in four patients with chronic CeH [58]. However, the effectiveness of occipital neuromodulation for CeH has not been tested in controlled studies.

Physical assessment & cervicogenic headache

Physiotherapy is the therapeutic option most frequently requested and used by individuals with CeH (around 75%) [59]. In fact, although the evidence in favor of physical therapy is somewhat limited, it is nevertheless greater than that supporting most medications, anesthetic injections and surgical procedures for CeH [60]. Clinical reasoning for the management of patients with CeH with physical therapy is clearly justified by the presence of several musculoskeletal impairments of the cervical spine in these patients. This association should be expected, given that the source of the pain is located at the cervical structures. Here, we briefly summarize the most updated data on this topic.

Restriction in cervical range of motion

A reduced cervical range of motion is advocated as one of the main features of CeH. Indeed, restricted cervical range of motion is considered a diagnostic criterion for CeH [1–4]. A restriction of cervical movement is a variable finding in other headaches, but CeH characteristically shows a clear limitation in neck motion [61,62] that is not related to age [63]. Furthermore, headache frequency and associated disability are correlated with such reduction of neck movement in patients with CeH [64].

Although any cervical spine motion can be limited, it seems clear that rotation is the most affected movement. It has been suggested that patients with CeH exhibit side-to-side differences of at least 10° in cervical rotation [65]. This assumption was based on the use of the cervical flexion–rotation test (FIGURE 1) as a clinical tool for the diagnosis of upper cervical spine restriction. This test is carried out by placing the cervical spine of the patient in flexion while the therapist passively rotates the head. The basis of the test is that cervical motion is limited to the C1–C2 level when the head is held in full flexion [66]. It has been found that subjects with CeH have an average of 28° of atlantoaxial rotation to the side of the headache as compared with an average rotation of 44° toward the asymptomatic side and in healthy people. The cervical flexion–rotation test has showed an overall diagnostic accuracy of 85–91% for CeH [67], with a positive cutoff value of 32° [68].

Upper cervical spine dysfunction

Physical therapists contend that they can diagnose cervical sources of headache by manual examination of the upper cervical

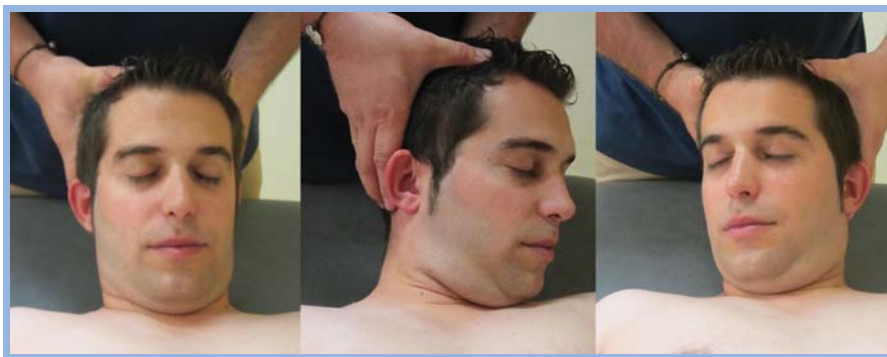

Figure 1. The cervical flexion–rotation test. The cervical spine of the patient is placed in flexion while the therapist passively rotates the head to each side.

joints with palpation and mobility tests [69,70]. For manual diagnosis of cervical spine dysfunctions, passive accessory intervertebral movements are proposed (FIGURE 2). The diagnosis of cervical spine dysfunction is made when a joint exhibits early end-feel, increased quality of resistance and reproduction of the patient's complaint [71,72]. A study published in 1988 compared manual diagnosis made by a physical therapist with that made with diagnostic blocks of cervical facets reporting an accuracy of 100% [73]. However, the sample size was small and the blocks were not controlled. Other studies have reported a good inter-rater reliability (κ : 0.4–0.8) for this kind of assessment in patients with CeH [74]. However, the validity of this assessment is not universally accepted [75,76].

There are several studies suggesting that upper cervical spine joint dysfunctions, particularly at C0/C1 and C1/C2 segments are highly prevalent in patients with CeH and that they can help to discriminate between CeH and other headaches such as tension-type headache or migraine [62,77–80]. A systematic review found very limited evidence for cervical dysfunction in patients with migraine other than in animal models [81].

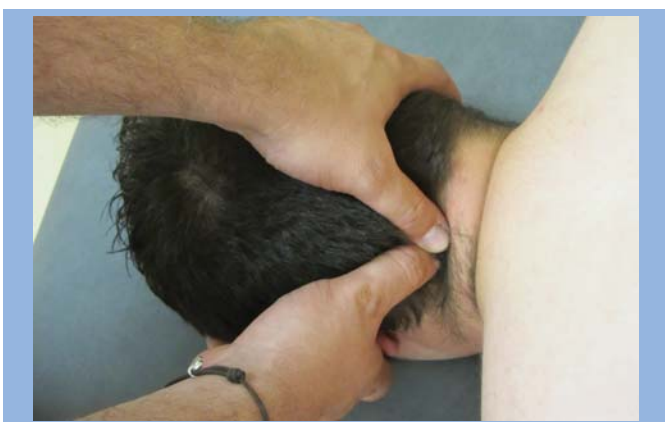

Figure 2. Posterior–anterior upper cervical spine joint mobilization (passive accessory intervertebral movements). The thumbs of the therapist make contact over the C1/C2 zygapophyseal joint. A posterior–anterior glide is applied to the joint.

Cervical muscle impairments

Patients with CeH also exhibit deficits in the strength of cervical flexor and extensor muscles as compared with patients suffering from migraine or tension-type headache [62,77,78,82]. There is preliminary evidence suggesting that cervical extensor muscle strength is particularly affected in CeH originating from trauma following a motor vehicle accident [83].

Some studies have revealed an altered motor strategy during the clinical execution of the craniocervical flexion test in patients with CeH. The craniocervical

flexion test represents a clinical indicator of impaired activation of the deep cervical flexor muscles, the longus capitis and colli [84]. The features assessed are the activation and isometric endurance of the deep cervical flexor muscles as well as their interaction with the superficial cervical flexor muscles during the performance of five progressive stages of increasing craniocervical flexion range of motion [85]. Patients with CeH show greater activation of the sternocleidomastoid muscle and reduced activity of the longus colli and longus capitis muscles [62,77,78,86].

Jull *et al.* demonstrated reduced cross-sectional area of the semispinalis capitis, but not longissimus capitis or trapezius muscles, measured at the level of C2 vertebrae on the symptomatic side in patients with CeH [77]. Such selective atrophy might be attributed to localized involvement of the upper cervical segments.

Musculoskeletal impairments can help differential diagnosis in CeH

It seems that no one of the clinical signs and symptoms are sufficient to discriminate CeH from other types of headache. If the source of the pain is the cervical spine, musculoskeletal dysfunctions should be mainly present in CeH and not in other headaches. Two studies investigated whether a cluster of musculoskeletal impairments can help to differentiate between patients with CeH and with other headaches. Those studies reported that the presence of palpable painful upper cervical joint dysfunction, restricted cervical spine extension and impaired performance on the craniocervical flexion test exhibited 100% sensitivity and 94% specificity to differentiate CeH from tension-type headache and migraine [77,78]. Although further research is clearly required to validate the capacity of this pattern of musculoskeletal impairments to differentially diagnose CeH, incorporating measures of cervical function to the physical examination appears promising as a clinical diagnostic aid. Additionally, the presence of these musculoskeletal impairments can orientate the proper management of these patients with physical therapy.

Physical therapy for cervicogenic headache

Numerous physical therapy interventions are proposed for the management of CeH: spinal manipulation (FIGURE 3), massage, stretching, connective tissue, dry needling (FIGURE 4), spinal

mobilization or neuromuscular approaches [87]. What is certain regarding CeH is that a cooperative effort should be considered in the treatment of these patients between physical therapists, neurologists and surgeons. A multidisciplinary effort leads to a better management of CeH [88]. The next section discusses the best evidence available for the different physical therapy options applied for CeH.

Spinal manipulation or mobilization

A survey conducted in Australia reported that spinal joint mobilization and/or manipulation were the manual therapies most used by physical therapists for the treatment of patients with CeH [89]. This preference is based on the clinical rationale that CeH represents referred pain elicited by nociceptive stimulation of upper cervical spine joints and that clinical trials involving patients with proven painful disorders of upper cervical zygapophyseal joints have shown significant relief of the headaches with treatment directed at cervical pain generators [90]. In addition, several studies have showed that noxious stimulation of the atlanto-occipital (C0/C1), lateral atlantoaxial (C1/C2) and C2–C3 zygapophyseal joints provoke pain in the occipital region [91–93]. Therefore, it seems logical that for effective management of CeH manual therapy, interventions should target the upper cervical spine joints, particularly the C1/C2 segment.

Several systematic reviews investigated the effectiveness of spinal manipulation in the management of headaches, particularly tension-type, migraine and CeH [94–98]. These reviews yielded inconsistent results, most probably because spinal manipulation is not equally effective for different headaches [99]. In fact, it seems that spinal joint manipulation might be effective for CeH. A recent systematic review found six randomized controlled trials suggesting that spinal joint manipulation was more effective than physical therapy, gentle massage, drug therapy or no intervention at all, whereas three trials showed no differences compared with placebo, manipulation, physical therapy, massage or waiting lists [100]. The highest quality randomized controlled trial was performed by Jull *et al.* [101]. These authors found that spinal joint manipulation and specific exercise targeted to deep neck flexor muscles reduced headache frequency and intensity in patients with CeH at short and long-term follow-up [101]. Haas *et al.* aimed to make preliminary estimates of the relationship between headache outcomes and the number of spinal manipulations received [102]. This study showed that a positive effect might be obtained in the range of 8–16 sessions for headache relief in CeH although a dose effect cannot be ruled out at this stage [102]. The application of spinal joint manipulations targeted to the upper cervical spine is recommended for CeH, but not for tension-type headache, in some evidence-based guidelines [103].

Nevertheless, the use of cervical spinal joint manipulations remain controversial because of the reported adverse reactions and subsequent concerns about safety. These adverse reactions range from minor conditions such as stiffness, increased pain and limitation in motion [104], to more serious injuries, including permanent neurological deficits, dissection of carotid or vertebral arteries and also death [105,106]. If all contraindications

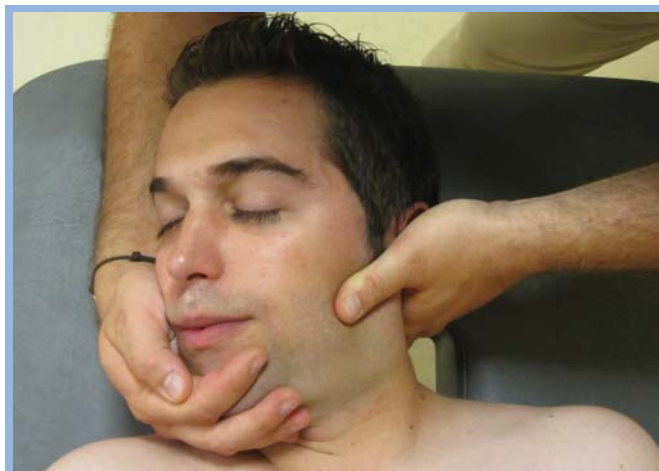


Figure 3. Upper cervical spine joint manipulation. The therapist uses the manipulative hand to localize the targeted segment (C1/C2) in rotation motion and uses the hand to perform a high-velocity, low-amplitude thrust into rotation, which is directed up toward the patient's contralateral eye.

and red flags are ruled out (i.e., osteoporosis, vertebral artery impairments or fracture), there is potential for a clinician to prevent 44.8% of adverse events associated with cervical manipulation. Yet, 10.4% of the events are unpreventable so that cervical spine manipulation carries an inherent risk even after a thorough exam and proper clinical reasoning [107]. In such a scenario, spinal joint mobilization techniques are considered to be safer than cervical spine manipulation. Certain studies have specifically investigated the effectiveness of joint mobilization of the upper cervical spine in patients with CeH. Youssef and Shanb found that upper cervical spine mobilization was more effective than massage therapy for reducing headache pain parameters and cervical range of motion in patients with CeH [108]. On the other hand, Hall *et al.* demonstrated that the application of sustained natural apophyseal glides in rotation targeted to the C1/C2 joint (FIGURE 5) led to an immediate reduction of pain in patients with CeH [109].

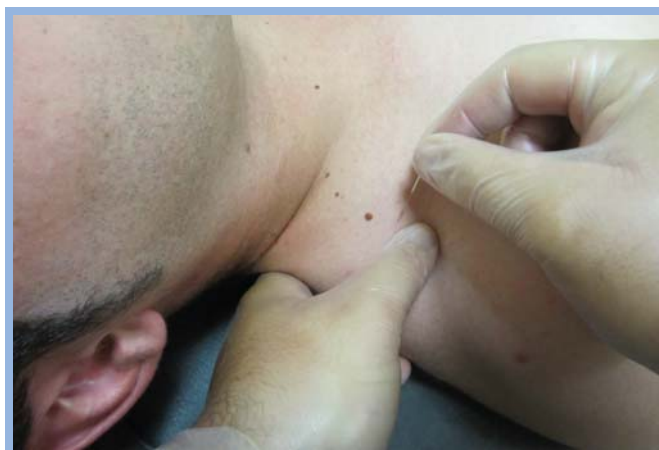


Figure 4. Dry needling applied over trigger points in the upper trapezius muscle.

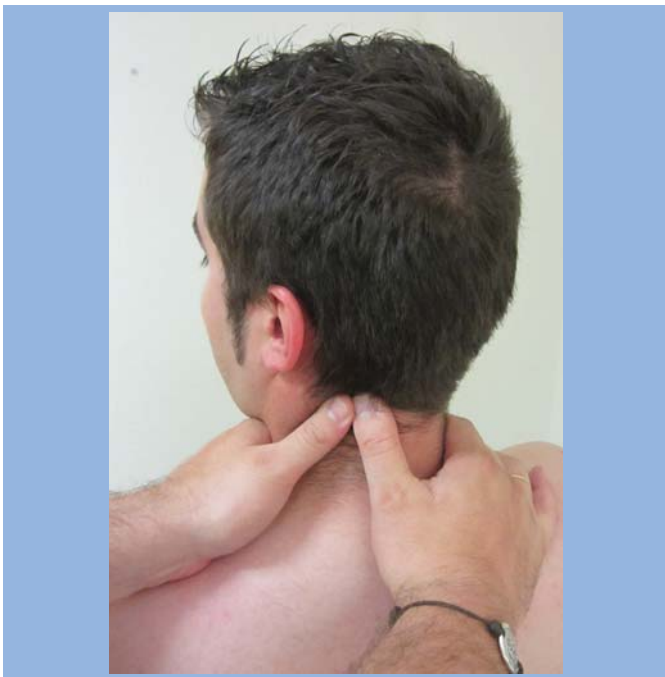

Figure 5. Sustained natural apophyseal glides in left rotation targeted to the C1/C2 joint. The therapist places the thumbs over the C1/C2 joint on the left side by applying a posterior–anterior and inferior–superior slide to the joint. The patient actively turns the head to the left in a pain-free range of motion.

Since there are close anatomical, functional and pathophysiological relationships between the cervical spine and the temporomandibular joint (TMJ) [110,111], some authors have suggested that the TMJ could also contribute to headache [112]. Two studies have determined that the inclusion of manual therapies targeted to the TMJ in combination with manual therapy targeted to the cervical spine was more effective for decreasing headache intensity and increasing neck function in patients with CeH [113,114]. These authors indicate that clinicians should

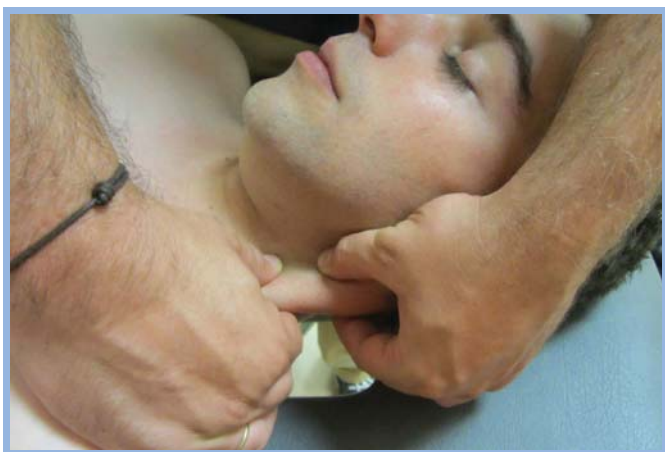

Figure 6. Manual therapy addressing trigger points in the sternocleidomastoid muscle. The fingers of the therapist grasp the taut band from both sides with a pincer palpation and stroke centrifugally away from the trigger point.

look for features of TMJ disorders when examining patients with CeH, particularly if previous treatment fails when directed to the cervical spine [113,114].

Soft tissue interventions

CeH pain has been mostly related to joint, disk and ligament disease of the upper cervical spine. However, the upper cervical nerves also receive afferent inputs from the muscle tissues. Accordingly, some authors claim that analyzing and managing of muscle imbalances may increase the effectiveness of physical therapy interventions for CeH [115–117]. There is one case report showing that treatment of sternocleidomastoid muscle trigger points (hypersensitive spots eliciting referred pain with stimulation) was effective for the management of CeH [118]. Otherwise, a pilot randomized controlled study revealed that manual therapy targeted to sternocleidomastoid muscle trigger points (FIGURE 6) was effective for improving headache intensity, pressure sensitivity, cervical range of motion and motor performance of the deep cervical flexors in individuals with CeH [119]. A recent systematic review has concluded that manual therapies targeted to either muscle or joints of the upper cervical spine might be an effective treatment for CeH, although this conclusion should be considered with caution at this stage since the studies mostly included participants with infrequent CeH [120].

Other physiotherapeutic interventions

Other therapy modalities, such as transcutaneous electrical nerve stimulation, have been investigated in patients with CeH with some positive results [121,122]. However, most of these studies were not controlled [123]. Some authors have suggested that transcutaneous electrical nerve stimulation should be applied to specific, not to all, patients with CeH [124].

Prognosis variables for physical therapy

The inconsistent results concerning physiotherapy management of CeH can be related to the fact that maybe not all therapeutic interventions are appropriate for all patients with CeH, or maybe not all patients with CeH will benefit from a particular intervention [125]. In line with this hypothesis, some studies have tried to identify potential prognostic variables to guide some physical therapy interventions in patients with CeH.

Niere found that a higher frequency of attacks predicted a positive response of patients with CeH to spinal manipulative therapy [126]. Fleming *et al.* reported that age and provocation or relief of headache with movement were factors associated with better outcomes in patients with CeH undergoing physical therapy [127]. Alternatively, Jull *et al.* could not find a concrete pattern of variables that might predict responsiveness to physiotherapy in patients with CeH [128].

It seems plausible that different therapeutic techniques might be effective for specific subgroups of patients. Therefore, sub-classification could help to identify those patients who are most likely to benefit of certain therapeutic approaches. As a consequence, the treatment choice for CeH should be made on an individual basis [129].

Complementary & alternative therapies

Complementary and alternative therapies are used by some patients with CeH, albeit they are not supported by scientific evidence. For instance, few studies have investigated the effects of acupuncture for management of CeH pain, and the results are controversial [130–132]. Future studies should analyze the effectiveness of several alternative interventions that are currently being used by patients with CeH.

Conclusions

CeH can be attributed to a disorder of the upper cervical spine or the adjacent soft tissues. The anatomical substratum of CeH is the convergence of trigeminal and upper cervical nociceptive inputs on the trigeminocervical nucleus caudalis. There are a variety of therapeutic approaches for the management of CeH, but scientific evidence of their effectiveness is scarce. So far, no medication drug has proven to be effective. GON blockades seem to be effective although the evidence is still limited. Cervical nerve blockades, facet joint injections and certain surgical procedures can be effective, but their use remains controversial. The presence of musculoskeletal impairments in the cervical spine can support the diagnosis and may be a helpful therapeutic aid. Several physical therapy techniques are proposed for this headache, with spinal manipulation and soft tissues interventions being the most commonly used by clinicians. However, the lack of solid evidence of positive effects and risks of serious complications for spinal manipulation should be considered in favor of other physical therapy options associated with less risk. The inconsistent results in the literature can be related to the fact that maybe not all therapeutic interventions are appropriate for all patients with CeH, or maybe not all individuals with CeH can benefit from a particular intervention. Future studies are clearly needed on this topic.

Expert commentary

In the current manuscript, we have summarized most updated evidence related to the management of CeH. Current evidence

suggests that physical therapy is probably the most proper therapeutic tool for the management of CeH. However, there are few randomized controlled trials investigating the effectiveness of physical therapy interventions in CeH. Additionally, the studies have investigated the effects of just one or two manual therapies in isolation, for example, spinal joint manipulation and/or massage, but they have not analyzed the effects of multimodal management. It seems plausible that not all patients with CeH will benefit from a particular intervention, and that treatment choices should be made on individual basis. Future studies should: investigate the effectiveness of multimodal interventions in the management of patients with CeH; and to identify subgroups of patients with CeH who will benefit from each particular intervention. In the authors' experience, individuals with CeH where the symptoms are reproduced during the physical examination are those most likely to benefit from physical therapy interventions.

Five-year view

There is preliminary evidence showing that physical therapy approaches should be applied for the management of patients with CeH. In the authors' opinion, future research should focus on implementing multimodal interventions on clinical practice. In addition, it is necessary to validate current clinical studies on prognostic factors (clinical prediction rules) to determine if a subgroup of patients with CeH can potentially benefit from any particular intervention. Although several advances have been made in the last few years, more research is needed for a better management of patients with CeH.

Financial & competing interests disclosure

The authors have no relevant affiliations or financial involvement with any organization or entity with a financial interest in or financial conflict with the subject matter or materials discussed in the manuscript. This includes employment, consultancies, honoraria, stock ownership or options, expert testimony, grants or patents received or pending, or royalties.

No writing assistance was utilized in the production of this manuscript.

Key issues

- Many treatments have been proposed for cervicogenic headache (CeH), but only few of them have been tested in randomized controlled trials and even fewer have proven effective.
- No drugs are effective for CeH.
- Local injections of anesthetics or nerve blocks have been used as diagnosis and treatment tools in patients with CeH, but the evidence for their effectiveness is limited.
- Surgical interventions for CeH are not sufficiently validated.
- The presence of several musculoskeletal impairments of the cervical spine in patients with CeH justifies the application of physical therapy interventions.
- There are several physical therapy interventions proposed for CeH (manipulation, massage, stretching, connective tissue, dry needling or spinal joint mobilization), but no solid evidence supports their effectiveness at this moment.
- The lack of solid evidence of positive effects and risks of serious complications for spinal manipulation should be considered in favor of other physical therapy options.
- It seems that certain subgroups of individuals with CeH could respond positively to specific interventions.

References

Papers of special note have been highlighted as:

- of interest
- of considerable interest

- Sjaastad O, Saunte C, Hovdahl H, Breivik H, Gronbaek E. "Cervicogenic" headache: a hypothesis. *Cephalalgia* 3, 249–56 (1983).
- Sjaastad O, Fredriksen TA, Pfaffenrath V. Cervicogenic headache: diagnostic criteria. *Headache* 30, 725–6 (1990).
- Sjaastad O, Fredriksen TA, Pfaffenrath V. Cervicogenic headache: diagnostic criteria; The Cervicogenic Headache International Study Group. *Headache* 38, 442–445 (1998).
- Headache Classification Subcommittee of the International Headache Society (IHS) The International Classification of Headache Disorders 2nd edition. *Cephalalgia* 24 (Suppl. 1), 9–160 (2004).
- Headache Classification Committee of the International Headache Society (IHS). The International Classification of Headache Disorders: 3rd Edition. *Cephalalgia* 33, 629–808 (2013).
- The third edition of the headache diagnostic criteria where the criteria of cervicogenic headache (CeH) has been updated.**
- Nilsson N. The prevalence of cervicogenic headache in a random population sample of 20–59 year olds. *Spine* 20, 1884–1888 (1995).
- Pereira Monteiro J, Barros J, Correia AP, Pinheiro J, Maio R. Prevalence of cervicogenic headache in an urban population of Porto. *Funct. Neurol.* 11, 133 (1996).
- Sjaastad O, Bakketeig L. Prevalence of cervicogenic headache: Väga study of headache epidemiology. *Acta Neurol. Scand.* 117, 173–180 (2008).
- Knackstedt H, Bansevicius D, Aaseth K, Grande RB, Lundqvist C, Russell MB. Cervicogenic headache in the general population: the Akershus study of chronic headache. *Cephalalgia* 30, 1468–1476 (2010).
- Bogduk N. Cervicogenic headache: anatomical basis and patho-physiological mechanisms. *Curr. Pain Headache Rep.* 5, 382–386 (2001).
- Bogduk N, Govind J. Cervicogenic headache: an assessment of the evidence on clinical diagnosis, invasive tests, and treatment. *Lancet Neurol* 8, 959–968 (2009).
- An updated review of pathophysiology of CeH.**
- Bolton S, O'Shaughnessy CT, Goadsby PJ. Properties of neurons in the trigeminal nucleus caudalis responding to noxious dural and facial stimulation. *Brain Res.* 1046, 122–129 (2005).
- Knackstedt H, Krakenes J, Bansevicius D, Russell M. Magnetic resonance imaging of craniocervical structures: clinical significance in cervicogenic headaches. *J. Headache Pain* 13, 39–44 (2012).
- Martelletti P, Stirparo G, Giacobuzzo M. Proinflammatory cytokines in cervicogenic headache. *Funct. Neurol.* 14, 159–162 (1999).
- Martelletti P. Proinflammatory pathways in cervicogenic headache. *Clin. Exp. Rheumatol.* 18, S33–S38 (2000).
- Martelletti P. Inflammatory mechanisms in cervicogenic headache: an integrative view. *Curr. Pain Headache Rep.* 6, 315–319 (2002).
- Tension Type and Cervicogenic Headache: Pathophysiology, Diagnosis and Treatment.* Fernández-de-las-Peñas C, Arendt-Nielsen L, Gerwin RD (Ed). Jones & Bartlett Publishers, Boston, MA, USA (2009).
- The first textbook focused on physical therapy for CeH from an evidence-based approach.**
- Aaseth K, Grande RB, Benth JS, Lundqvist C, Russell MB. 3-Year follow-up of secondary chronic headaches: the Akershus study of chronic headache. *Eur. J. Pain* 15, 186–192 (2011).
- Gallagher RM. Cervicogenic headache. *Expert Rev. Neurother.* 7, 1279–1283 (2007).
- Martelletti P, van Suijlekom H. Cervicogenic headache: practical approaches to therapy. *CNS Drugs* 18, 793–805 (2004).
- Haldeman S, Dagenais S. Cervicogenic headaches: a critical review. *Spine J.* 1, 31–46 (2001).
- Inan E, Inan N. Conservative treatment in cervicogenic headache. In: *Cervicogenic Headache: Basic Concept.* Sjaastad O, Fredriksen G, Bono G (Eds), Smith-Gordon, Great Britain, UK 101–103 (2003).
- Pareja JA, Sjaastad O. Chronic paroxysmal hemi crania and hemi crania continua: Interval between indomethacin administration and response. *Headache* 36, 20–23 (1996).
- Bovim G, Sjaastad O. Cervicogenic headache: responses to nitroglycerin, oxygen, ergotamine and morphine. *Headache* 33, 249–252 (1993)
- Pareja JA, Bovim G. Cervicogenic headache: differential diagnosis. In: *Cervicogenic Headache: Basic Concepts.* Sjaastad O, Fredriksen TA, Bono G, Nappi G (Eds). Smith Gordon, Great Britain, UK 59–65 (2003).
- Freund BJ, Schwartz M. Treatment of chronic cervical-associated headache with botulinum toxin A: a pilot study. *Headache* 40, 231–236 (2000).
- Linde M, Hagen K, Salvesen Ø, Gravdahl GB, Helde G, Stovner LJ. Onabotulinum toxin A treatment of cervicogenic headache: a randomised, double-blind, placebo-controlled crossover study. *Cephalalgia* 31, 797–807 (2011).
- An important clinical study showing the lack of effects of botulinum toxin A in CeH.**
- Langevin P, Peloso PM, Lowcock J, Nolan M, Weber J, Gross A, Roberts J, Goldsmith CH, Graham N, Burnie SJ, Haines T. Botulinum toxin for subacute/chronic neck pain. *Cochrane Database Syst. Rev.* 7, CD008626 (2011).
- Ashkenazi A, Blumenfeld A, Napchan U *et al.* Peripheral nerve blocks and trigger point injections in headache management: a systematic review and suggestions for future research. *Headache* 50, 943–952 (2010).
- Naja ZM, El-Rajab M, Al-Tannir MA, Ziade FM, Tawfik OM. Occipital nerve blockade for cervicogenic headache: a double-blind randomized controlled clinical trial. *Pain Pract.* 6, 89–95 (2006).
- Naja ZM, El-Rajab M, Al-Tannir MA, Ziade FM, Tawfik OM. Repetitive occipital nerve blockade for cervicogenic headache: expanded case report of 47 adults. *Pain Pract.* 6, 278–284 (2006).
- Inan N, Ceyhan A, Inan L, Kavakyoglu O, Alptekin A, Unal N. C2/C3 nerve blocks and greater occipital nerve blocks in cervicogenic headache treatment. *Funct. Neurol.* 16, 239–243 (2011).
- Vincent M. Greater occipital nerve blockades in cervicogenic headache. *Funct. Neurol.* 13, 78–79 (1998).
- Anthony M. Cervicogenic headache: prevalence and response to local steroid therapy. *Clin. Exp. Rheumatol.* 18, S59–S64 (2000).
- Bovim G, Sand T. Cervicogenic headache, migraine without aura and tension-type headache. Diagnostic blockade of greater occipital and supra-orbital nerves. *Pain* 51, 43–48 (1992).

- 36 Terzi T, Karakurum B, Üçler S, Inan LE, Tulunay C. Greater occipital nerve blockade in migraine, tension-type headache and cervicogenic headache. *J. Headache Pain* 3, 137–141 (2002).
- 37 Vicent M, Luna R, Scandiuzzi D, Novis SA. Greater occipital nerve blockade in cervicogenic headache. *Arg. Neuropsiquiatr.* 56, 720–725 (1998).
- 38 Weibelt S, Andress-Rothrock D, King W, Rothrock J. Suboccipital nerve blocks for suppression of chronic migraine: safety, efficacy, and predictors of outcome. *Headache* 50, 1041–1044 (2010).
- 39 Baron EP, Cherian N, Tepper SJ. Role of greater occipital nerve blocks and trigger point injections for patients with dizziness and headache. *Neurologist* 17, 312–317 (2011).
- 40 Bovim G, Berg R, Dale L. Cervicogenic headache: anaesthetic blockades of cervical nerves (C2–C5) and facet joint (C2/C3). *Pain* 49, 315–320 (1992).
- 41 Narouze SN, Casanova J, Mekhail N. The longitudinal effectiveness of lateral atlantoaxial intra-articular steroid injection in the treatment of cervicogenic headache. *Pain Med.* 8, 184–188 (2007).
- 42 Zhou L, Hud-Shakoor Z, Hennessey C, Ashkenazi A. Upper cervical facet joint and spinal rami blocks for the treatment of cervicogenic headache. *Headache* 50, 657–663 (2010).
- 43 Martelletti P, Di Sabato F, Granata M *et al.* Epidural steroid-based technique for cervicogenic headache diagnosis. *Funct. Neurol.* 13, 84–87 (1998).
- 44 Martelletti P, Di Sabato F, Granata M *et al.* Epidural corticosteroid blockade in cervicogenic headache. *Eur. Rev. Med. Pharmacol. Sci.* 2, 31–36 (1998).
- 45 Martelletti P, Di Sabato F, Granata M *et al.* Failure of long-term results of epidural steroid injection in cervicogenic headache. *Eur. Rev. Med. Pharmacol. Sci.* 2, 10 (Abstract) (1998).
- 46 Blume HG. Cervicogenic headache: radiofrequency neurotomy and the cervical disc and fusion. *Clin. Exp. Rheumatol.* 18 (2 Suppl. 19), S53–S58 (2000).
- 47 Van Suijlekom HA, Van kleef M, Barendse GA, Sluijter ME, Sjaastad O, Weber WE. Radiofrequency cervical zygapophyseal joint neurotomy for cervicogenic headache: a prospective study of 15 patients. *Funct. Neurol.* 13, 297–303 (1998).
- 48 Blume HG. Treatment of cervicogenic headaches: radiofrequency neurotomy to the sinuvertebral nerves to the upper cervical disc and to the outer layer of the C3 nerve root or C4 nerve root respectively. *Funct. Neurol.* 13, 83–84 (1998).
- 49 Mehnert MJ, Freedman M. Update on the role of z-joint injection and radiofrequency neurotomy for cervicogenic headache. *PMR* 5, 221–227 (2013).
- 50 Bovaira M, Peñarrocha M, Peñarrocha M, Calvo A, Jiménez A, March R. Radiofrequency treatment of cervicogenic headache. *Med. Oral Patol. Oral. Cir. Bucal.* 18, 293–297 (2013).
- 51 Stovner LJ, Kolstad F, Helde G. Radiofrequency denervation of facet joints C2–C6 in cervicogenic headache: a randomized, double-blind, sham-controlled study. *Cephalalgia* 24, 821–830 (2004).
- 52 Haspelslagh SR, Van Suijlekom HA, Lamé IE, Kessels AG, van Kleef M, Weber WE. Randomised controlled trial of cervical radiofrequency lesions as a treatment for cervicogenic headache. *BMC Anesthesiol.* 6, 1 (2006).
- 53 Van Boxem K, van Eerd M, Brinkhuizen T *et al.* Radio- frequency and pulsed radiofrequency treatment of chronic pain syndromes: the available evidence. *Pain Pract.* 8, 385–393 (2008).
- 54 Zhang J, Shi DS, Wang R. Pulsed radiofrequency of the second cervical ganglion (C2) for the treatment of cervicogenic headache. *J. Headache Pain* 12, 569–571 (2011).
- 55 Halim W, Chua NH, Vissers KC. Long-term pain relief in patients with cervicogenic headaches after pulsed radiofrequency application into the lateral atlantoaxial (C1-2) joint using an anterolateral approach. *Pain Pract.* 10, 267–271 (2010).
- 56 Gabrhelík T, Michálek P, Adamus M. Pulsed radiofrequency therapy versus greater occipital nerve block in the management of refractory cervicogenic headache: a pilot study. *Prague Med. Rep.* 112, 279–873 (2011).
- 57 Jansen J. Surgical treatment of non-responsive cervicogenic headache. *Clin. Exp. Rheumatol.* 18(2 Suppl. 9), S67–S70 (2000).
- 58 Rodrigo-Royo MD, Azcona JM, Quero J, Lorente MC, Acín P, Azcona J. Peripheral neurostimulation in the management of cervicogenic headache: four case reports. *Neuromodulation* 8, 241–248 (2005).
- 59 Eisenberg DM, Davis RB, Ettner SL, Appel S, Wilkey S, Van Rompay M *et al.* Trends in alternative medicine use in the United States, 1990–97: results of a follow-up national survey. *JAMA* 280, 1569–1575 (1998).
- 60 Haldeman S, Dagenais S. Choosing a treatment for cervicogenic headache: when? what? how much? *Spine J.* 10, 169–171 (2010).
- 61 Zwart JA. Neck mobility in different headache disorders. *Headache* 37, 6–11 (1997).
- 62 Zito G, Jull G, Story I. Clinical tests of musculoskeletal dysfunction in the diagnosis of cervicogenic headache. *Man Ther.* 11, 118–129 (2006).
- 63 Smith K, Hall T, Robinson K. The influence of age, gender, lifestyle factors and sub-clinical neck pain on the cervical flexion-rotation test and cervical range of motion. *Man Ther.* 13, 552–559 (2008).
- 64 Vavrek D, Haas M, Peterson D. Physical examination and self-reported pain outcomes from a randomized trial on chronic cervicogenic headache. *J. Manipulative Physiol. Ther.* 33, 338–348 (2010).
- 65 Hall TM, Briffa K, Hopper D, Robinson K. Comparative analysis and diagnostic accuracy of the cervical flexion-rotation test. *J. Headache Pain* 11, 391–397 (2010).
- 66 Stratton S, Bryan JM. Dysfunction, evaluation and treatment of the cervical spine and thoracic inlet. In: *Orthopaedic physical therapy*. Donattelli R, Wooden M (Eds). Churchill Livingstone, NY, USA (1994).
- 67 Ogincin M, Hall T, Robinson K, Blackmore AM. The diagnostic validity of the cervical flexion-rotation test in C1/2-related cervicogenic headache. *Man Ther.* 12, 256–262 (2007).
- 68 Hall T, Briffa K, Hopper D. The influence of lower cervical joint pain on range of motion and interpretation of the flexion-rotation test. *J. Man Manip. Ther.* 18, 126–131 (2010).
- 69 Greenman PE. *Principles of manual medicine*. Lippincott Williams & Wilkins, PA USA (1996).
- 70 Maitland G, Hengeveld L, Banks K, English K. *Maitland's Vertebral Manipulation*. Butterworth-Heinemann, Oxford, UK (2001).
- 71 Jull G, Treheaven J, Versace G. Manual examination: is pain provocation a mayor cue for spinal dysfunction? *Aust. J. Physiother.* 40, 159–165 (1994).

- 72 Seffinger MA, Hruby RJ. Evidence-based manual medicine: a problem-oriented approach. Philadelphia, Saunders Elsevier (2007).
- 73 Jull G, Bogduk N, Marsland A. The accuracy of manual diagnosis for cervical zygapophysial joint pain syndromes. *Med. J. Aust.* 148, 233–236 (1988).
- 74 Jull G, Zito G, Trott P, Potter H, Shirley D, Carolyn R. Inter-examiner reliability to detect painful upper cervical joint dysfunction. *Aust. J. Physiother.* 43, 125–129 (1997).
- 75 King W, Lau P, Lees R, Bogduk N. The validity of manual examination in assessing patients with neck pain. *Spine J.* 7, 22–26 (2007).
- 76 Van Trijffel E, Anderegg O, Bossuyt PM, Lucas C. Inter-examiner reliability of passive assessment of inter-vertebral motion in the cervical and lumbar spine: a systematic review. *Man Ther.* 10, 256–269 (2005).
- 77 Jull G, Amiri M, Bullock-Saxton J, Darnell R, Lander C. Cervical musculo-skeletal impairment in frequent intermittent headache. Part 1: subjects with single headaches. *Cephalalgia* 27, 793–802 (2007).
- An important clinical study showing that the inclusion of musculoskeletal neck disorders can help to differentiate CeH from other primary headaches.
- 78 Amiri M, Jull G, Bullock-Saxton J, Darnell R, Lander C. Cervical musculo-skeletal impairment in frequent intermittent headache. Part 2: Subjects with multiple headaches. *Cephalalgia* 27, 891–898 (2007).
- 79 Gijsberts TJ, Duquet W, Stoekart R, Oostendorp P. Pain provocation tests for C0-4 as a tool in the diagnosis of cervicogenic headache (abstract). *Cephalalgia* 19, 436 (1999).
- 80 Hall T, Briffa K, Hopper D, Robinson K. Reliability of manual examination and frequency of symptomatic cervical motion segment dysfunction in cervicogenic headache. *Man Ther.* 15, 542–546 (2010).
- 81 Robertson BA, Morris ME. The role of cervical dysfunction in migraine: a systematic review. *Cephalalgia* 28, 474–483 (2008).
- 82 Watson DH, Trott PH. Cervical headache: an investigation of natural head posture and upper cervical flexor muscle performance. *Cephalalgia* 13, 272–284 (1993).
- 83 Dumas JP, Arsenault A, Boudreau G *et al.* Physical impairments in cervicogenic headache: traumatic vs. non-traumatic onset. *Cephalalgia* 21, 884–893 (2001).
- 84 Falla D, Jull G, O’Leary S, Dall’alba P. Further evaluation of and EMG technique for assessment of the deep cervical flexor muscles. *J. Electromyogr. Kinesiol.* 16, 621–628 (2006).
- 85 Falla D, Jull G, Dall’Alba P, Rainoldi A, Merletti R. An electromyographic analysis of the deep cervical flexor muscles in performance of cranio-cervical flexion. *Phys. Ther.* 83, 899–906 (2003).
- 86 Jull G, Barrett C, Magee R, Ho P. Further clinical clarification of the muscle dysfunction in cervical headache. *Cephalalgia* 19, 179–185 (1999).
- 87 Grant T, Niere K. Techniques used by manipulative physiotherapists in the management of headaches. *Austr. J. Physiother.* 46, 215–222 (2000).
- 88 Rana MV. Managing and treating headache of cervicogenic origin. *Med. Clin. North Am.* 97, 267–280 (2013).
- An updated review of pathophysiology of CeH.
- 89 Jull G. Use of high and low velocity cervical manipulative therapy procedures by Australian manipulative physiotherapists. *Austr. J. Physiother.* 48, 189–193 (2002).
- 90 Becker WJ. Cervicogenic headache: evidence that the neck is a pain generator. *Headache* 50, 699–705 (2010).
- An important review suggesting that the cervical spine is involved in CeH.
- 91 Dreyfuss P, Michaelsen M, Fletcher D. Atlanto-occipital and lateral atlanto-axial joints pain patterns. *Spine* 19, 1125–1131 (1994).
- 92 Paluzzi A, Belli A, Lafuente J, Wasserberg J. Role of the C2 articular branches in occipital headache: An anatomical study. *Clin. Anat.* 19, 497–502 (2006).
- 93 Aprill C, Axinn MJ, Bogduk N. Occipital headaches stemming from the lateral atlanto-axial (C1-C2) joint. *Cephalalgia* 22, 15–22 (2002).
- 94 Vernon H, McDermaid CS, Hagino C. Systematic review of randomized clinical trials of complementary/alternative therapy in the treatment of tension-type and cervicogenic headache. *Complement Ther. Med.* 7, 142–155 (1999).
- 95 Bronfort G, Assendelft WJ, Evans R, Haas M, Bouter L. Efficacy of spinal manipulation for chronic headache: a systematic review. *J. Manipulative Physiol. Ther.* 24, 457–466 (2001).
- 96 Astin JA, Ernst E. The effectiveness of spinal manipulation for the treatment of headache disorders: a systematic review of randomized clinical trials. *Cephalalgia* 22, 617–623 (2002).
- 97 Bronfort G, Nilsson N, Haas M *et al.* Non-invasive physical treatments for chronic/recurrent headache. *Cochrane Database Syst. Rev.* CD001878 (2004)
- 98 Lenssinck ML, Damen L, Verhagen AP *et al.* The effectiveness of physiotherapy and manipulation in patients with tension-type headache: a systematic review. *Pain* 112, 381–388 (2004).
- 99 Posadzki P, Ernst E. Systematic reviews of spinal manipulations for headaches: an attempt to clear up the confusion. *Headache* 51, 1419–1425 (2011).
- The most updated systematic review on spinal manipulation for headaches.
- 100 Posadzki P, Ernst E. Spinal manipulations for cervicogenic headaches: a systematic review of randomized clinical trials. *Headache* 51, 1132–1139 (2011).
- The most updated systematic review on spinal manipulation for CeH.
- 101 Jull G, Trott P, Potter H *et al.* A randomized controlled trial of exercise and manipulative therapy for cervicogenic headache. *Spine* 27, 1835–1843 (2002).
- 102 Haas M, Spegman A, Peterson D, Aickin M, Vavrek D. Dose response and efficacy of spinal manipulation for chronic cervicogenic headache: a pilot randomized controlled trial. *Spine J.* 10, 117–128 (2010).
- 103 Bryans R, Descarreaux M, Duranleau M, Marcoux H, Potter B, Ruegg R, Shaw L, Watkin R, White E. Evidence-based guidelines for the chiropractic treatment of adults with headache. *J. Manipulative Physiol. Ther.* 34, 274–89 (2011)
- 104 Cagnie B, Vinck E, Beernaert A, Cambier D. How common are side effects of spinal manipulation and can these side effects be predicted? *Man Ther.* 9, 151–156 (2004).
- 105 Ernst E. Manipulation of the cervical spine: a systematic review of case reports of serious adverse events, 1995-2001. *Med. J. Aust.* 176, 376–380 (2002).
- 106 Oppenheim JS, Spitzer DE, Segal DH. Nonvascular complications following spinal manipulation. *Spine J.* 5, 660–666 (2005).
- 107 Puentedura EJ, March J, Anders J, Perez A, Landers MR, Wallmann HW, Cleland JA. Safety of cervical spine manipulation: are adverse events preventable and are

- manipulations being performed appropriately? a review of 134 case reports. *J. Man Manip. Ther.* 20, 66–74 (2012).
- 108 Youssef EF, Shanb AS. Mobilization versus massage therapy in the treatment of cervicogenic headache: a clinical study. *J. Back Musculoskelet. Rehabil.* 26, 17–24 (2013).
- 109 Hall T, Chan HT, Christensen L, Odenthal B, Wells C, Robinson K. Efficacy of a C1-C2 self-sustained natural apophyseal glide (SNAG) in the management of cervicogenic headache. *J. Orthop. Sports Phys. Ther.* 37, 100–107 (2007).
- 110 Bevilaqua-Grossi D, Chaves TC, de Oliveira AS. Cervical spine signs and symptoms: perpetuating rather than predisposing factors for temporomandibular disorders in women. *J. Applied Oral Sci.* 15, 259–264 (2007).
- 111 Olivo SA, Bravo J, Magee DJ, Thie NM, Major PW, Flores-Mir C. The association between head and cervical posture and temporomandibular disorders: a systematic review. *J. Orofacial. Pain* 20, 9–23 (2006).
- 112 Goncalves DA, Camparis CM, Speciali JG, Franco AL, Castanharo SM, Bigal ME. Temporomandibular disorders are differentially associated with headache diagnoses: a controlled study. *Clin. J. Pain* 27, 611–615 (2011).
- 113 Von Piekartz H, Lüdtke K. Effect of treatment of temporomandibular disorders (TMD) in patients with cervicogenic headache: a single-blind, randomized controlled study. *Cranio* 29, 43–56 (2011).
- 114 Von Piekartz H, Hall T. Orofacial manual therapy improves cervical movement impairment associated with headache and features of temporomandibular dysfunction: a randomized controlled trial. *Man. Ther.* 18, 345–350 (2013).
- 115 Moore MK. Upper crossed syndrome and its relationship to cervicogenic headache. *J. Manipulative Physiol. Ther.* 27, 414–620 (2004).
- 116 Lewit K. *Manipulative Therapy in the Rehabilitation of the Locomotor System (2nd Edition)*. Butterworth-Heinemann, Oxford, UK 79–80 (1991).
- 117 Christensen K. Manual muscle testing and postural imbalance *Dynamic Chiropractic* 15, 2 (2000).
- 118 Roth JK, Roth RS, Weintraub JR and Simons DG. Cervicogenic headache caused by myofascial trigger points in the sternocleidomastoid: a case report. *Cephalalgia* 27, 375–380 (2007).
- 119 Bodes-Pardo G, Pecos-Martín D, Gallego-Izquierdo T, Salom-Moreno J, Fernández-de-las-Peñas C, Ortega-Santiago R. Manual treatment for cervicogenic headache and active trigger point in the sternocleidomastoid muscle: a pilot randomized clinical trial. *J. Manipulative Physiol. Ther.* 36, 403–411 (2013).
- 120 Chaibi A, Russell MB. Manual therapies for cervicogenic headache: a systematic review. *J. Headache Pain* 13, 351–359 (2012).
- **The most updated systematic review on manual therapies for CeH.**
- 121 Li C, Zhang XL, Ding H, Tao YQ, Zhan HS. [Comparative study on effects of manipulation treatment and transcutaneous electrical nerve stimulation on patients with cervicogenic headache] (Chinese). *Zhong Xi Yi Jie He Xue Bao* 5, 403–406 (2007).
- 122 Tarhan C, Inan L, Karaoglan B, Yorgancyoglu R. TENS treatment in cervicogenic headache. *Phys. Med.* 2, 13–17 (1999).
- 123 Kroeling P, Gross A, Goldsmith CH, Burnie SJ, Haines T, Graham N, Brant A. Electrotherapy for neck pain. *Cochrane Database Syst. Rev.* 4, CD004251 (2009).
- 124 Sjaastad O, Fredriksen T, Jorgensen JV. Electrical stimulation in headache treatment. For separate headache(s) or for headache generally? *Funct. Neurol.* 24, 53–59 (2009).
- 125 Fernández-de-las-Peñas C. Physical therapy and exercise in headache. *Cephalalgia* 28 (Suppl. 1), 36–38 (2008).
- 126 Niere K. Can subjective characteristics of benign headache predict manipulative physiotherapy treatment outcome. *Aust. J. Physiother.* 44, 87–93 (1998).
- 127 Fleming R, Forsythe S, Cook C. Influential variables associated with outcomes in patients with cervicogenic headache. *J. Man. Manip. Ther.* 15, 155–164 (2007).
- 128 Jull G, Stanton W. Predictors of responsiveness to physiotherapy management of cervicogenic headache *Cephalalgia* 25, 101–108 (2005).
- 129 Vincent MB. Cervicogenic headache: A review comparison with migraine, tension-type headache, and whiplash. *Curr. Pain Headache Rep.* 14, 238–243 (2010).
- 130 Hu WQ, Xu SW. [Clinical observation on treatment of cervicogenic headache with tuina and acupuncture]. *Zhong Xi Yi Jie He Xue Bao* 3, 310–311 (2005)
- 131 Lü YX, Shan QH. [Clinical observation on treatment of cervicogenic headache with turtle-probing needling at Tianzhu (BL 10)]. *Zhongguo Zhen Jiu* 26, 796–798 (2006).
- 132 Yang XC, Zhou YM, Lv M, Wang XC, Qiu ZL. [Clinical observation on the treatment of cervicogenic headache by muscular acupuncture stimulation therapy]. *Zhen Ci Yan Ji* 34, 72 (2009).